

Department of Uro pathology

UK00000

DIAGNOSTIC REPORT

DIANON SYSTEMS
840 RESEARCH PARKWAY

OKLAHOMA CITY, OK 73104

Accession No. UH0000000	Chart No.	Sex M	D.O.B. 10/00/1900 82 Yrs	Page 1 of 1
Patient Name SAMPLE, PATIENT			Life ID:***** Phone:000 000 0000	Collected 12/12/12
Requesting Physician SAMPLE, PHYSICIAN, MD				Received 12/14/12
Referring Physician				Reported 12/18/12
Clinical Data No clinical data specified No therapy				

CYTOLOGIC DIAGNOSIS

SPECIMEN TYPE: Bladder Wash

GROSS DESCRIPTION:

Received is 90ml of light yellow, clear, fixed urine.

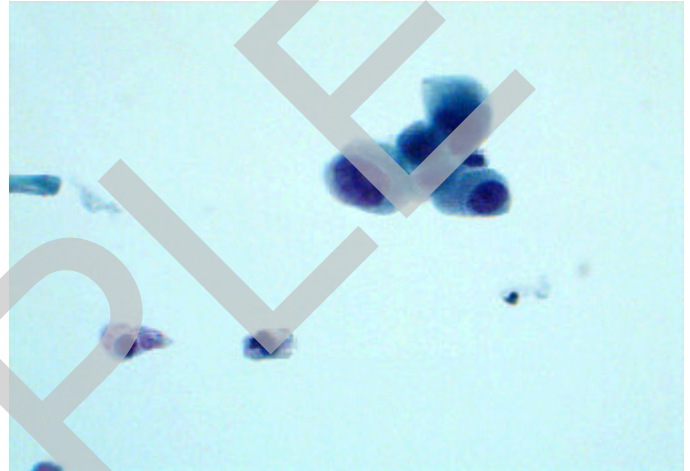
MICROSCOPIC DESCRIPTION:

Highly abnormal urothelial cells with markedly atypical nuclear features: severe hyperchromasia, coarsened chromatin texture, pleomorphism and increased nucleocytoplasmic ratio.

***DIAGNOSIS:**

Positive for malignancy. High-grade urothelial carcinoma and/or carcinoma in situ. Mild acute inflammation.

PHOTOMICROGRAPH

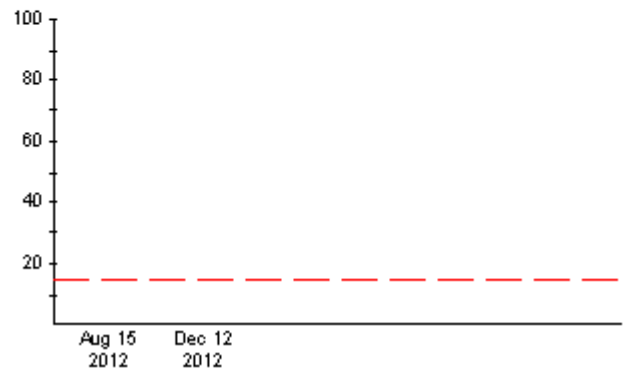


DIAGNOSTIC TREND REPORT

Positive	_____▲_____
Suspicious	_____
Dysplasia	_____▲_____
Atypical/Abnl	_____
Negative	_____

DNA HISTOGRAM

DNA TREND GRAPH



Brian D. Wedel *Xiao Cong Peng*

Brian D. Wedel, CT(ASCP)

Xiao Cong Peng, M.D.